

# Percutaneous Radiofrequency Ablation of Hepatocellular Carcinoma on Cirrhosis: State of the Art and Future Perspectives

Antonio Giorgio\*

*Infectious Diseases and Interventional Ultrasound Unit, D. Cotugno" Hospital, Naples, Italy*

Received: April 7, 2009; Accepted: July 9, 2009; Revised: July 30, 2009

**Abstract:** Radiofrequency (RF) ablation has gained great popularity in the treatment of Hepatocellular Carcinoma (HCC) on cirrhosis and is replacing Percutaneous Ethanol Injection (PEI) in treating 3cm or less HCC nodules. Its necrotic effect is more predictable than that of PEI and therefore RF can achieve a longer local tumor progression control and survival. In the last four years many data on its efficacy have been added in the Literature and long-term results on 3-5-year survival are available. In this review article data of the last 4 years on percutaneous RF ablation of HCC on cirrhosis are discussed in order to give an answer to questions put forward on this matter at 2000 EASL Barcelona Consensus Conference. Moreover, new perspectives in the percutaneous treatment of some form of advanced HCC (the so-called *percutaneous thrombectomy*) are presented together with some patents in the treatment of HCC.

**Keywords:** Cirrhosis, hepatocellular carcinoma, radiofrequency ablation, percutaneous interventional ultrasound.

## INTRODUCTION

Hepatocellular Carcinoma (HCC) is one of the most common forms of cancer and it arises mainly in cirrhotic livers [1-4]. HCC is one of the deadliest cancers worldwide and it accounts for approximately 549.000 cancer deaths each year [5]. The incidence is about 3-4% per year, but screening programs have now allowed the diagnosis at an early stage, when the tumor is eligible for curative treatments [3]. Liver transplantation (LT) is nowadays the standard of care for patients with HCC and underlying liver cirrhosis. However, the number of available livers is still limited and therefore liver resection or percutaneous ablation techniques, such as Percutaneous Ethanol Injection (PEI) or Radiofrequency Thermal Ablation (RF), can be considered for most of the patients. According to the last guidelines of the European Association for the Study of Liver Disease (EASLD), percutaneous ablation techniques have achieved a relatively high rate of complete response in selected patients, similarly to liver transplantation and liver resection, and can be classified as curative /effective treatments [6]. When in 2001 EASL guidelines were defined, PEI was the standard of choice while other ablative techniques, more aggressive and more expensive so as RF or Interstitial Laser Therapy or micro-waves, should be compared to PEI in controlled prospective randomised trials. Since then, RF has gained great popularity in treatment of HCC and is replacing PEI.

The aim of this review article was to present the last data available on percutaneous RF ablation of HCC on cirrhosis with the aim of trying to reply to the questions put forward at the 2000 EASL Barcelona Consensus Conference.

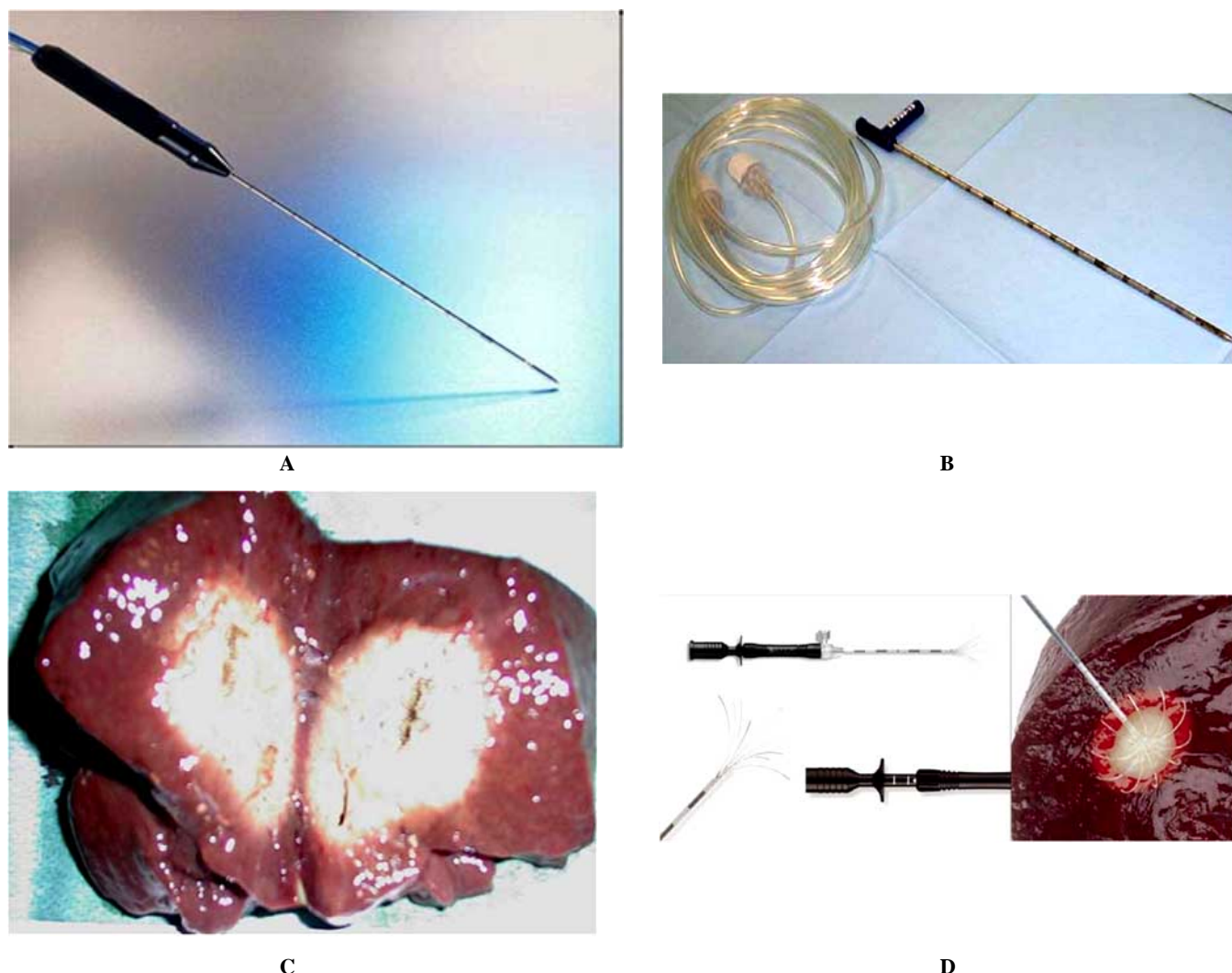
## RF DEVICES

Generally, percutaneous ablation is performed under Ultra-sound (US) guidance, which represents the best imaging modality in guiding the insertion of the electrode needle into the tumor, in monitoring the diffusion of energy within it, in controlling the withdraw of electrode needle and new insertions of electrode into the tumor. Richard *et al.* discussed in US20080146912 the use of inter-communicator process for simultaneous MRI thermography and radio frequency ablation [7]. Moreover, with the increasing use of Contrast Enhanced Ultrasound (CEUS) [8, 9], guidance and monitoring of RF ablation under CEUS can facilitate the performance of the interventional procedure in evaluating the hyper-vascular portion of the tumor, so to reduce the number of RF sessions.

Percutaneous ablation of HCC can be obtained using monopolar or multipolar energy by inserting one or more electrode needles into the tumor [10] Fig. (1). Heat is generated in the tissue around the needle or between the needles by molecular friction and ionic dissipation [11-13]. The multipolar method can achieve a volume of necrosis approximately more than double that a lesion treated with a simple monopolar needle [14, 15].

There are three types of commercially available RF electrode needle: expandable electrode, internally cooled electrode and saline - enhanced electrode [16] Fig. (2). Up to now there are no reports comparing all three types of electrodes. A recent study by Shibata *et al.* compared the effectiveness of expandable and internally cooled needles in the treatment of small HCC less than 3cm [17]. The effectiveness was 95% in the internally cooled needle and 93% in the expandable electrodes, while major complications were 0 and 2.8%, respectively. No differences were found between the two electrodes regarding overall survival, local tumor progression and disease-free survival [16]. Our experience with saline-enhanced electrode needles, even if not controlled, is similar to the former results with the two

\*Address correspondence to this author at the Infectious Diseases and Interventional Ultrasound Unit, D. Cotugno" Hospital, Via Quagliariello 54, 80131 Naples, Italy; Tel: + 39081 5908278; Fax: +39 081 5908278; E-mail: assanui1@virgilio.it



**Fig. (1).** A/D: RF commercially available devices

**1A:** Cool tip-needle

**1B:** Perfused electrode needle

**1C:** Example of induced necrosis by the perfused needle in an ex-vivo liver, pig liver: a 5 x 3cm oval necrotic area is appreciable

**1D:** Expandable 9 hooklets electrode needle

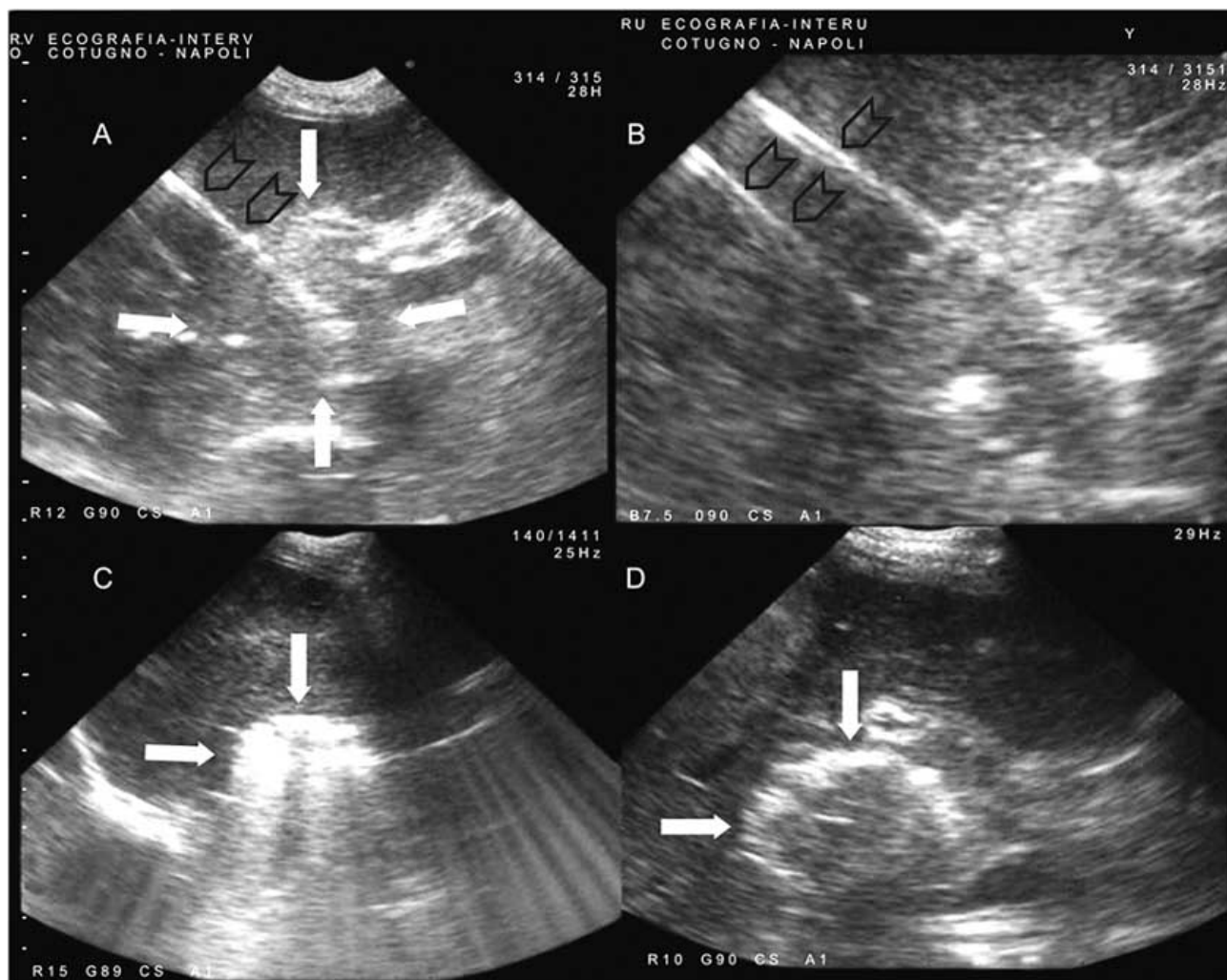
other types of electrodes commercially available [17]. Lin *et al.* compared four RF devices in treating HCC nodules less than 4cm: RF 2000 (maximum power 100W) and RF 3000 (maximum power 200W) with LeVeen expandable electrodes with a maximum dimension of 3.5cm or 4cm internally cooled single electrodes with a thermal dimension of 3cm and a RITA generator with expandable electrodes with a maximum dimension of 5cm [18]. They concluded that complete necrosis and local tumor progression were similar among devices [18]. Hansier *et al.* treated 38 HCC patients with a multiple saline enhanced electrode needles and showed that effectiveness was comparable with other established ablation techniques [19].

#### RATES OF NECROSIS

It is clear now that the percentage of induced RF necrosis is strictly depending from size of treated HCC nodules as proved both at imaging evaluation and in explanted liver.

After percutaneous RF ablation, on radiological evaluation (i.e. enhanced CT or MRI) most of authors reported complete necrosis in most of treated lesions < 3cm [10, 17, 20-29]. The percentage of necrosis decreases with the increasing of tumor size. Livraghi *et al.* treated 114 cirrhotic patients with 126 HCCs larger than 3cm using an expandable cooled electrode: 80 tumors were 3.1-5cm in diameter, and 46 were 5.1-9.5cm in diameter. At imaging, complete necrosis was observed in 60 lesions (47.6%), nearly complete necrosis in 40 tumors (31.7%) and partial necrosis was observed in 26 HCCs (20.6%) [30]. In our experience with saline-perfused electrodes, percutaneous RF ablation achieved 95% complete necrosis in HCC nodules up to 3cm, 83% complete response in HCCs ranging from 3 to 4cm, 47 % necrosis in lesions ranging from 4 to 5cm and only 12% in nodules from 5 to 8.5cm [17].

In explanted livers, the rate of necrosis is smaller than the percentage observed on imaging modalities, i.e. enhanced CT or MRI. Mazzaferro *et al.* found that, in patients who



**Fig. (2).** A/D: Example of sonographic-guided multipolar percutaneous RF ablation.

**2A:** Large HCC (5.2cm), (arrows) with the first multipolar electrode needle (open arrow) inserted within the tumor

**2B:** Two electrodes needle (open arrows) are inserted within the tumor and the generator is on function

**2 C:** At the end of RF ablation the HCC nodule appears completely hyperechoic (white arrows)

**2D:** The day after procedure the HCC ablated appears well demarcated.

underwent liver transplantation after RF ablation, complete necrosis was present in 55% of explants (vs 70% of radiological response) [31]. Lu *et al.* reported complete response after LT in 65% of the tumors < 3cm (vs 85% radiological complete response) [32, 33].

Therefore, other techniques have been added to percutaneous RF in the treatment of large and unresectable HCCs. Rossi *et al.* reported good results in 62 cirrhotic patients with large and unresectable HCC treated with one or two percutaneous RF sessions after occlusion of the tumor arterial supply [22]. Yamasaki *et al.* performed RF ablation of 47 large HCC with cooled electrodes combined with hepatic arterial balloon occlusion and found that balloon-occluded RF is superior to standard RF for the treatment of HCC when larger coagulation volumes are required [34].

Sakr and co-workers assessed the short term effect of sequential RF and PEI in the management of HCC nodules larger than 5cm [35]. They adopted a protocol of overlapping RF applications, followed by repeated PEI sessions and

concluded that such combined protocol is more effective than RF alone [35]. Recently, Lencioni *et al.* assessed safety and efficacy of doxorubicin-eluting bead (DEB)-enhanced RF ablation in the treatment of human HCC [36]. Twenty patients with a single HCC nodule ranging in diameter between 3.3 and 7.0cm underwent intra-arterial DEB administration after evidence of residual viable tumor following standard percutaneous RF. These authors concluded that intra-arterial DEB administration is safe and results in a high rate of complete responses in patients with residual tumor activity after standard RF [36]. OzeKi presented in US20060293386 a new method for treating cancer [37]. Noujaim *et al.* reported some methods in cancer treatment using vascular occlusion in combination with one or more therapies in US20070098724 [38].

## LONG TERM SURVIVAL

Because of the absence of randomised controlled trials (RCTs) comparing percutaneous ablation techniques versus no treatment, the primary goal of recent studies was survival.

**Table 1. Clinical Studies on Percutaneous RF Ablation on HCC with Cirrhosis**

Author	Year	Journal	Aim of the Study	Needle
Rossi <i>et al.</i>	1996	AJR	Small HCC survival	Expandable
Livraghi <i>et al.</i>	2000	Radiology	Medium-large HCC/efficacy	Cool-tip
Curley <i>et al.</i>	2000	Ann Surg	Efficacy	Cool-tip
Rossi <i>et al.</i>	2000	Radiology	RF +tumor blood supply occlusion	Expandable
Goldberg <i>et al.</i>	2000	Cancer	Pathological condition/efficacy	Cool-tip
Giorgio <i>et al.</i>	2003	AJR	Efficacy	Perfused
Lencioni <i>et al.</i>	2005	Radiology	Survival expandable needle	
Seror <i>et al.</i>	2008	Radiology	Efficacy/survival	Multipolar electrode
<b>Comparative study</b>				
Lin <i>et al.</i>	2004		Gastroenterology	
Shiina <i>et al.</i>	2004		Gastroenterology	
Brunello <i>et al.</i>	2008		Scand J Gastroenterol	
<b>Meta-analysis</b>				
Orlando <i>et al.</i>	2009		Am J Gastroenterol	
CHO <i>et al.</i>	2009		Hepatology	
Bunza <i>et al.</i>	2009		BMC Gastroenterol	

Table 1 reports the main clinical studies on percutaneous RF ablation of HCC on cirrhosis. The first 5-year cumulative survival curve in the treatment of HCC on cirrhosis using percutaneous RF was reported by Rossi *et al.* in 1996 [10]. One, 3 and 5- year overall survival rates of 39 treated patients with 54 HCC nodules less than 3cm were 94%, 61% and 40%, respectively. In 2001 the same group reported a 5-year survival rate of 33% in 88 RF treated cirrhotic patients with an HCC nodule up to 3,5cm [39].

Lencioni *et al.* treated with percutaneous RF 187 cirrhotic patients with either a single HCC < 5cm or maximum three nodules less than 3cm [40]. This author obtained 97%, 71% and 48% survival rates at 1,3 and 5-years, respectively. In the experience of Lencioni and co-workers survival was strictly depending by Child's class of cirrhosis and multiplicity of nodules: in fact, Child A patients with a single HCC nodule had 1, 3 and 5-year survival rates of 100%, 89%, and 61% respectively and the median survival time was 65 months in their series [40].

After the publication of 2001 EASL guidelines, in the last 4 years several authors focused their attention in comparing the different percutaneous ablation techniques used in clinical practice such as RF and PEI (see "comparison with other therapeutic modalities" section below). Hence, following these studies, other results, in terms of survival, are now available.

Lin *et al.* in a group of 52 cirrhotic patients treated with percutaneous RF reported an overall survival rate of 96%, 84% and 78% at 1,2 and 3 years, respectively [41].

Shiina *et al.* reported 74% 4-year survival rate in 232 cirrhotic patients and HCC nodules satisfying Milan's criteria for liver transplantation [42].

Finally, a recent study by the italian group of Brunello and co-workers reported 50% 4-year survival rate in 70 HCC patients who underwent percutaneous RF [43].

## COMPLICATIONS

Percutaneous RF ablation has shown to be a safe and effective procedure when performed by experienced operators and following normal established technique [44]. In a multicenter study that enrolled 2.320 patients who underwent percutaneous RF ablation with an internally cooled electrode needle, Livraghi *et al.* reported 6 deaths (0.3%) [45]; 2.2 % major complications were encountered in the study [45]. Deaths were due to multi-organ failure (1 case), haemoperitoneum (3 cases) or liver failure (2 cases). Major complications were haemorrhage, seeding, pyogenic abscess formation and intestinal perforation [45].

Zagoria *et al.* reported one death for liver abscess formation [46].

Buscarini *et al.*, in a series of 166 patients treated by RF with expandable needle, did not report any death and a rate of 4% major complications were encountered [47].

De Baère *et al.* reported 1.6% mortality rate and 12 % major rate complication rates related to RF application [48].

In our experience, on 338 cirrhotic patients treated with a perfused electrode needle mortality rate was 0.3% and major

complication rate was 0.6% [49]. One death was due to decompensation of liver cirrhosis in a Child B cirrhotic patient with a single 2cm HCC. Major complications were an abscess formation in one patient with a 3.5cm HCC located in the VI segment and a self-limiting subcutaneous cellulitis [49]. In this series, no cutaneous or abdominal wall seeding was observed [49].

RF of small HCC is a safe procedure even in high-risk locations [50-52]. Major complications that can be encountered more frequently are haemoperitoneum or abscess formation; this last complication can be encountered after ablation sessions of HCC nodules located in the VI segment: heat can reach the bowel wall and can determine perforation of the large bowel so that intestinal germs can reach the liver and can induce abscess formation [49]. Such abscess can be managed percutaneously [49, 53].

Acute cholecystitis following percutaneous RF ablation due to heat injury to gallbladder wall has also been reported [54] as well as some cases of haemobilia: therefore, some authors suggest not to treat HCC nodules close to gallbladder. But the experience of Chopra and co-workers [55] and our interventional routine experience (unpublished data) clearly show that tumors adjacent to the gallbladder is feasible and appears safe to be treated as described above.

## COMPARISON WITH OTHER THERAPEUTIC MODALITIES

After the Consensus Conference of Barcelona in June 2000, the 2001 published EASL guidelines stated that, in properly selected patients with HCC, percutaneous ablation achieves a relatively high rate of complete response, similar to that of liver transplantation or hepatic resection [6]. According to 2001 EASL guidelines, PEI was the standard percutaneous technique and "thus more expensive and invasive options, such as RF, cryotherapy or laser, should be compared with PEI in controlled randomised trials assessing not only tumor response, but also long-term survival and costs" [6]. From 2004 several randomised controlled trials have been published comparing PEI and RF in the treatment of small HCC. Two of these prospective trials have some biases because of selection of patients or because of the short term survival time reported (only two years) [56, 57]. Therefore, only three full-length published RCTs, comparing PEI and RF in the treatment of HCC on cirrhosis, were considered for recent meta-analysis studies assessing 3-year survival.

Lin *et al.* compared PEI and RF in treatment of HCC < 4cm. One hundred and fifty seven patients with 186 HCC 4cm or less were randomly assigned to three groups: 52 in the conventional PEI, 53 in the higher dose PEI and 52 in RF ablation [41]. Complete tumor necrosis was 85%, 92% and 96% in the conventional PEI group, higher-dose PEI group and RF ablation group, respectively. Overall survival rate was highest in the RF group *vs* the conventional group,  $p = 0.14$ , *vs* the higher - dose group,  $p = 0.023$ . In particular, at 1, 2 and 3 years the overall survival rate was 96%, 84% and 78%, respectively [41]. Local tumor progression was lowest in the RF group (*vs* the conventional PEI,  $p = 0.012$ ; *vs* the higher - dose group,  $p = 0.037$ ). Cancer free survival rate was highest in the RF group (*vs* the conventional PEI group,

$p = 0.19$ ; *vs* the higher - dose PEI,  $p = 0.024$ ). The Authors concluded that RF ablation yielded better clinical outcomes than conventional PEI and higher-dose in treating HCC 4cm or less [41].

Shiina *et al.* prospectively randomised 232 patients with HCC (3 or fewer lesions) each 3cm or less to receive PEI and RF. Four - year survival rate was 74% in RF patients and 57 in PEI treated patient [42]

RF had a 46% smaller risk of death, a 43% smaller risk of overall recurrence and a 88% smaller risk of local tumor progression than PEI. Adverse events were not different between the two groups. Shiina and co-workers concluded that, judging from higher survival but similar adverse events, RF is superior to PEI for small HCC.

The most recent work was published by the Italian group of Brunello and co-workers [43]. One hundred and thirty nine cirrhotic child A or B patients were prospectively randomised to percutaneous treatment with RF or PEI: they have 177 nodules 15-30mm, 1 or 3 nodules. The primary end point was the complete response one year after ablation; the secondary end point was early complete response, complications rate and survival. Complete response was 65.7% for RF patients and 36% for PEI group. Complications were observed in 10 patients in the PEI group and in 12 patients in the RF group. Four year survival was identical in the two groups without any significant statistical difference [43].

Regarding the comparison with surgery, two interesting works have been recently published. Chen and colleagues reported the results of a prospective randomised trial comparing RF and partial hepatectomy for small HCC [58]. One hundred and eighty cirrhotic patients were randomly assigned to RF or surgery. the 1, 2 3 and 4-year survival rates after RF and surgery were 95.8%, 82.1%, 71.4%, 67.9% and 93.3%, 82.3%, 73.4%, 64.0%, respectively [58].

The corresponding disease- free-survival rates were 85.9%, 69.3%, 64.1%, 46.4% and 86.6%, 76.8%, 69%, 51.6%, respectively [58]. Statistically, there was no difference between the two treatments. The Author's conclusion is that percutaneous RF was as effective as surgical resection in the treatment of solitary and small HCC; moreover percutaneous RF has the advantage over surgical resection in being less invasive [58].

This concept has been stressed again in the very recent report by Livraghi and co-workers appeared in Hepatology one year ago [59]. The Livraghi's work replies to the ancient question if surgery is better than percutaneous ablation in the treatment of small HCC. The term small HCC is now characterized as an HCC nodule less or equal to 2cm in diameter [59]. In this study 218 cirrhotic patients with a single HCC 2cm or less underwent RF. Two primary end points that could be easily compared with those reported for resective surgery were evaluated: 1) the rate of sustained, local complete response and 2) the rate of treatment related complications. The secondary end point was 5-year survival in the 100 patients whose tumors had been considered potentially operable. Peri-operative mortality, major complications and 5-year survival rates were 0%, 1.8% and 68%, respectively. The Authors concluded that, compared with resection, RF is less invasive, with lower complication

rate and similar local control and survival [59]; more-over, in the opinion of Livraghi and colleagues, these data indicate that RF can be considered the treatment of choice for patients with single HCC 2cm or less, even when surgical resection is possible [59].

After these reports, three recent meta-analyses of controlled randomised trials have been published comparing RF and PEI in the treatment of HCC on cirrhosis [60, 61].

In the meta-analysis of Orlando *et al.* [60] RF ablation was superior to PEI in the treatment of small HCC with respect to overall survival, 1, 2, and 3 years survival rates, 1, 2, and 3 cancer-free survival rates, and tumor response.

In the meta-analysis of Cho *et al.* [61] RF ablation significantly improved 3-year survival status for patients with HCC > 2cm; when compared to PEI, however, the Authors conclude that large scale RCTs are needed for assess the overall survival of patients with lesions < 2cm [61].

Finally the same conclusions were recently reported by Bouza *et al.* who analysed the efficacy and safety of RF versus PEI in treating non surgical HCC [62].

## CURRENT & FUTURE DEVELOPMENTS

The data presented so far clearly indicate that RF is a valid alternative to surgery for HCC nodules up to 3cm or less, so that, in the opinion of some authors, it should be considered the first line therapy for single early 2 m HCCs, in patients with compensated liver disease, even if, in our opinion, it should be added “in patients unsuitable for LT”.

Moreover, a large amount of data support the idea that percutaneous RF is safe and effective also in tumors up to 4 cm in diameter. According to the 2005 guidelines of AASLD, PEI and RF are equally effective for HCC < or equal to 2m [63]. The necrotic effect of RF is more predictable in all tumor sizes and its efficacy is clearly superior to PEI in larger tumors [34].

Nevertheless, patients with portal system invasion are always excluded from percutaneous RF ablation. HCC is a tumor with great tendency to invade portal system and portal vessels invasion is still found in 12-70% of cases [64-67]. Prognosis of patients with HCC extended in the portal vein is very poor and a median survival time of 2.7-4.0 months in untreated patients has been reported [68, 69]. There is only a report by Seror and colleagues which deals with HCC and segmental portal invasion treated with multipolar RF [14]. But in this work patients with neoplastic thrombosis of main branches of portal vein (right or left branch) and main portal trunk were clearly excluded. Therefore, on the basis of our previous experience in treating both large HCCs and neoplastic thrombus of left or right branch of portal vein with ONE - SHO PEI [70], we speculated to treat percutaneously with heat both the intra-parenchymal HCC nodules and the neoplastic thrombus into the main portal trunk (MPT) [71].

We treated 13 cirrhotic Child A patients with a single HCC nodule up to 5cm in diameter extended the main portal trunk (MPT) up to 3,5cm from bifurcation (Group 1). Fourteen patients (10 males, 4 females; mean age 69, range 67-73 yrs) matched for sex, age, number of nodules, length

of portal vein tumor thrombus (MPVTT) and Child classification of liver cirrhosis with 14 HCC nodules (3.6-4.8cm) extended in the MPT refused any kind of treatment and represented the control group (Group 2). RF ablation was performed percutaneously using a saline-enhanced perfused electrode needle, firstly on the neoplastic thrombus and then on the intra-parenchymal HCC nodule. The procedure was defined successful when both complete necrosis of HCC nodule and recanalization of portal vein were achieved.

Ten patients achieved complete response and in 3 patients RF ablation was unsuccessful. Cumulative survival rate was 77%, 77%, and 77% at 1,2 and 3 years in RF treated patients (Group 1) and 43% and 0% at 6 and 12 months in untreated patients (Group 2) respectively, with a statistical significant difference (log-rank test:  $p < 0.0001$ ),

Only few minor complications were observed [71-73].

These data showed that RF can destroy both the HCC intra-parenchymal nodule and the accompanied neoplastic thrombus in the MPT with high efficacy and low rate of complications.

How can these results be explained?

In our opinion the main factor was the selection of only patients with a single up to 5cm HCC nodule and with well compensated liver disease.

Nevertheless, these preliminary results need further confirmation, either by us and others, in a larger series of patients and a longer time of observation, so to control that they can be maintained over time (5 years). Obviously, this procedure must be performed by an experienced operator in interventional ultrasound.

## ACKNOWLEDGEMENTS

Author thanks Dr. Antonella Di Sarno, M.D., for her support in the preparation of the manuscript.

## CONFLICT OF INTEREST

None.

## REFERENCES

- [1] Monto A, Wright TL. The epidemiology and prevention of hepatocellular carcinoma. *Semin Oncol* 2001; 28 (5): 441-449.
- [2] Fattovich G, Stroffolini T, Zagni I, Donato E. Hepatocellular carcinoma in cirrhosis: Incidence and risk factors. *Gastroenterol* 2004; 127 (5 Suppl): S53-50
- [3] Masami M, Makuuchi M. Treatment of hepatocellular carcinoma accompanied by portal vein tumor thrombus. *World J Gastroenterol* 2006; 21 (47): 7561-7567.
- [4] Takizawa D, Kakizaki S, Sohara N, *et al.* Hepatocellular carcinoma with portal vein tumor thrombosis: Clinical characteristics, prognosis, and patient survival analysis. *Dig Dis Sci* 2007; 52 (11): 3290-3295.
- [5] Reichman TW, Tiffany A, Millis JM, Testa G. Uncharacteristically early fatal intraperitoneal rupture of hepatocellular carcinoma following transarterial chemoembolisation. *Dig Liver Dis* 2009; 41: 175-176.
- [6] Bruix J, Sherman M, Llovet JM, *et al.* Clinical management of hepatocellular carcinoma. Conclusion of the Barcelona-2000 EASL-Conference. *J Hepatol* 2001; 35: 421-430.
- [7] Richard, H. M., Gullapalli, R. P., Zhang, B.: US20080146912 (2008).

- [8] Solbiati L, Ierace T, Tonolini M, Cova L. Guidance and monitoring of radiofrequency liver tumor ablation with contrast-enhanced ultrasound. *Eur J Radiol* 2004; 51 (Suppl): S19-23.
- [9] Giorgio A, de Stefano G, Farella N, *et al.* Percutaneous echo-guided ablation of hepatocellular carcinoma (HCC), guidance and monitoring with contrast enhanced ultrasound (CEUS). *Dig Liver Dis* 2009; 41 (A11): 5.
- [10] Rossi S, Di Stasi M, Buscarini E, *et al.* Percutaneous RF interstitial thermal ablation in the treatment of hepatic cancer. *Am J Roentgenol* 1996; 167: 759-768.
- [11] Buscarini L, Fornari F, Rossi S. Interstitial radiofrequency hyperthermia in the treatment of small hepatocellular carcinoma: Percutaneous US-guided of electrode needle. In: Andereg A, Desplaned PA, Otto R, Henner H, Eds. *Ultraschall-diagnostik* 91; Berlin: Springer-Verlag 1992: 218-222.
- [12] Rossi S, Fornari F, Buscarini L. Percutaneous ultrasound-guided radiofrequency electrocautery for the treatment of small hepatocellular carcinoma. *J Intervent Radiol* 1993; 8: 97-103.
- [13] Rossi S, Di Stasi M, Buscarini E, *et al.* Percutaneous radiofrequency interstitial thermal ablation in the treatment of small hepatocellular carcinoma. *Cancer J Sci Am* 1995; 1: 73-81.
- [14] Seror O, N'Kontchou G, Ibraliu M, *et al.* Large (> or = 5cm) HCCs: Multipolar RF ablation with three internally coded bipolar electrodes: Initial experience in 26 patients. *Radiology* 2008; 248 (1): 288-96.
- [15] Giorgio A, de Stefano G, Ferraioli G. Multipolar RF ablation of large HCC on cirrhosis. *Proceeding Euroson* 2006.
- [16] Shibata T, Shibata T, Maetani Y, Isoda H, Hiraoka M. Radiofrequency ablation for small hepatocellular carcinoma: Prospective comparison of internally cooled electrode and expandable electrode. *Radiology* 2006; 238 (1): 346-353.
- [17] Giorgio A, Tarantino L, de Stefano G, *et al.* Percutaneous sonographically guided saline-enhanced radiofrequency ablation of hepatocellular carcinoma. *Am J Roentgenol* 2003; 181 (2): 479-484.
- [18] Lin SM, Lin CC, Chen WT, Chen YC, Hsu CW. Radiofrequency ablation for hepatocellular carcinoma: A prospective comparison of four radiofrequency devices. *J Vasc Interv Radiol* 2007; 18 (9): 1118-1125.
- [19] Hänsler J, Frieser M, Tietz V, *et al.* Percutaneous radiofrequency ablation of liver tumors using multiple saline-perfused electrodes. *J Vasc Interv Radiol* 2007; 18 (3): 405-410.
- [20] Livraghi T, Lazzaroni S, Meloni F. Radiofrequency thermal ablation of hepatocellular carcinoma. *Eur J Ultrasound* 2001; 13: 159-166.
- [21] Goldberg SN, Kamel IR, Kruskal JB, *et al.* Radiofrequency ablation of hepatic tumors: Increased tumor destruction with adjuvant liposomal doxorubicin therapy. *Am J Roentgenol* 2002; 179: 93-101.
- [22] Rossi S, Garbagnati F, Lencioni R, *et al.* Percutaneous radiofrequency ablation of nonresectable HCC after occlusion of tumor blood supply. *Radiology* 2000; 217: 119-126.
- [23] Pacella CM, Bizzarri G, Ceconi P, *et al.* HCC: Long-term results of combined treatment with laser thermal ablation and TACE. *Radiology* 2001; 219: 669-678.
- [24] Kurkochi K, Watanabe S, Masaki T, *et al.* Comparison between combination therapy of PEI and RFA alone for patients with HCC. *World J Gastroenterol* 2005; 11: 1426-1432.
- [25] Seror O, N'Kontchou G, Haddar D, *et al.* Large infiltrative HCC: Treatment with percutaneous intraarterial ethanol injection alone or in combination with conventional PEI. *Radiology* 2005; 234: 299-309.
- [26] Seror O, N'Kontchou G, Tin Htar TM, *et al.* Ethanol versus radiofrequency ablation for treatment of small hepatocellular carcinoma in patients with cirrhosis: A retrospective study of efficacy and cost. *Gastroenterol Clin Biol* 2006; 30 (11): 1265-1273.
- [27] Curley SA, Izzo F, Ellis LM, Nicolas VJ, Vallone P. Radiofrequency ablation of hepatocellular cancer in 110 patients with cirrhosis. *Ann Surg* 2000; 232: 381-391.
- [28] Rossi S, Buscarini E, Fornari F, *et al.* Percutaneous treatment of small hepatic tumors by an expandable RF needle electrode. *Am J Roentgenol* 1998; 170 (4): 1015-1022.
- [29] Lencioni R, Crocetti L, Pina MC, Cioni D. Percutaneous image-guided radiofrequency ablation of liver tumors. *Abdom Imaging* 2009; 34(5): 547-56.
- [30] Livraghi T, Goldberg SN, Lazzaroni S, *et al.* Hepatocellular carcinoma: Radio-frequency ablation of medium and large lesions. *Radiology* 2000; 214 (3): 761-768.
- [31] Mazzaferro V, Battiston C, Perrone S, *et al.* Radiofrequency ablation of small hepatocellular carcinoma in cirrhotic patients awaiting liver transplantation: A prospective study. *Ann Surg* 2004; 240: 900-909.
- [32] Lu DS, Yu NC, Raman SS, *et al.* Radiofrequency ablation of hepatocellular carcinoma: Success as defined by histologic examination of the explanted liver. *Radiology* 2005; 234 (3): 954-960.
- [33] Lu DS, Yu NC, Tso WK, *et al.* Percutaneous radiofrequency ablation of hepatocellular carcinoma as a bridge to liver transplantation. *Hepatology* 2005; 41: 1130-1137.
- [34] Yamasaki T, Kimura T, Kurokawa F, *et al.* Percutaneous radiofrequency ablation with cooled electrodes combined with hepatic arterial balloon occlusion in hepatocellular carcinoma. *J Gastroenterol* 2005; 40 (2): 171-178.
- [35] Sakr AA, Saleh AA, Moeaty AA, Moeaty AA. The combined effect of radiofrequency and ethanol ablation in the management of large hepatocellular carcinoma. *Eur J Radiol* 2005; 54 (3): 418-425.
- [36] Lencioni R, Crocetti L, Petrucci P, *et al.* Doxorubicin-eluting bead-enhanced radiofrequency ablation of hepatocellular carcinoma: A pilot clinical study. *J Hepatol* 2008; 49 (2): 217-222.
- [37] Ozeki, T.: US20060293386A1 (2006).
- [38] Noujaim, A., Person, R. H., Stewart, M. W., Hirsche, B. D.: US20070098724 (2007).
- [39] Buscarini L, Buscarini E, Di Stasi M, *et al.* Percutaneous radiofrequency ablation of small hepatocellular carcinoma: Long-term results. *Eur Radiol* 2001; 11 (6): 914-921.
- [40] Lencioni R, Cioni D, Crocetti L, *et al.* Early-stage hepatocellular carcinoma in patients with cirrhosis: Long-term results of percutaneous image-guided radiofrequency ablation. *Radiology* 2005; 234: 961-967.
- [41] Lin SM, Lin CJ, Lin CC, Hsu CW, Chen YC. Radiofrequency ablation improves prognosis compared with ethanol injection for hepatocellular carcinoma  $\leq$  4cm. *Gastroenterology* 2004; 127: 1714-1723.
- [42] Shiina S, Teratani T, Obi S, *et al.* A randomised controlled trial of radiofrequency ablation with ethanol injection for small hepatocellular carcinoma. *Gastroenterology* 2005; 129: 122-130.
- [43] Brunello F, Veltri A, Carucci P, *et al.* Radiofrequency ablation versus ethanol injection for early hepatocellular carcinoma: A randomised controlled trial. *Scand J Gastroenterol* 2008; 43 (6): 727-735.
- [44] Goldberg SN, Gazelle GS, Compton CC, Mueller PR, Tanable KK. Treatment of intrahepatic malignancy with radiofrequency ablation: Radiologic-pathologic correlation. *Cancer* 2000; 88 (11): 2452-2463.
- [45] Livraghi T, Solbiati L, Meloni MF, *et al.* Treatment of focal liver tumors with percutaneous radio-frequency ablation: Complications encountered in a multicenter study. *Radiology* 2003; 226: 441-451.
- [46] Zagoria RJ, Chen MY, Shen P, Levine EA. Complications from radiofrequency ablation of liver metastases. *Am Surg* 2002; 68: 204-209.
- [47] Buscarini E, Buscarini L. Radiofrequency thermal ablation with expandable needle of focal liver malignancies: Complication report. *Eur Radiol* 2004; 14: 31-37.
- [48] de Baère T, Risse O, Kuoch V, *et al.* Adverse events during radiofrequency treatment of 582 hepatic tumors. *Am J Roentgenol* 2003; 181: 695-700.
- [49] Giorgio A, Tarantino L, de Stefano G, Coppola C, Ferraioli G. Complications after percutaneous saline-enhanced radiofrequency ablation of liver tumors: 3-year experience with 336 patients at a single center. *Am J Roentgenol* 2005; 184: 207-211.
- [50] Kang TW, Rhim H, Kim EY, *et al.* Percutaneous radiofrequency ablation for the hepatocellular carcinoma abutting the diaphragm: Assessment of safety and therapeutic efficacy. *Korean J Radiol* 2009; 10 (1): 34-42.
- [51] Lee MW, Kim YJ, Park SW, *et al.* Percutaneous radiofrequency ablation of liver dome hepatocellular carcinoma invisible on ultrasonography: A new targeting strategy. *Br J Radiol* 2008; 81 (965): e130-134.
- [52] Seror O, Haddar D, N'Kontchou G, *et al.* radiofrequency ablation for the treatment of liver tumors in the caudate lobe. *J Vasc Interv Radiol* 2005; 16 (7): 981-190.

- [53] Giorgio A, Ferraioli G. Liver abscess formation after radiofrequency ablation in patients with hepatocellular carcinoma. *Am J Roentgenol* 2006; 186 (2): 582-583.
- [54] Francica G, Iodice G, Marone G. Acute thermal injury of the gallbladder in the course of interstitial radiofrequency hyperthermia treatment for hepatocellular carcinoma. *Eur J Ultrasound* 1996; 4: 123-127.
- [55] Chopra S, Dodd GD 3rd, Chanin MP, Chintapalli KN. Radio-frequency ablation of hepatic tumors adjacent to the gallbladder: Feasibility and safety. *Am J Roentgenol* 2003; 180 (3): 697-701.
- [56] Livraghi T, Goldberg SN, Lazzaroni S, *et al.* Small hepatocellular carcinoma: Treatment with radio-frequency ablation versus ethanol injection. *Radiology* 1999; 210: 655-661.
- [57] Lencioni RA, Allgaier HP, Cioni D, *et al.* Small hepatocellular carcinoma in cirrhosis: Randomized comparison of radio-frequency thermal ablation versus percutaneous ethanol injection. *Radiology* 2003; 228 (1): 235-240.
- [58] Chen MS, Li JQ, Zheng Y, *et al.* A prospective randomized trial comparing percutaneous local ablative therapy and partial hepatectomy for small hepatocellular carcinoma. *Ann Surg* 2006; 243 (3): 321-328.
- [59] Livraghi T, Meloni F, Di Stasi M, *et al.* Sustained complete response and complications rates after radiofrequency ablation of very early hepatocellular carcinoma in cirrhosis: Is resection still the treatment of choice? *Hepatology* 2008; 47 (1): 82-89.
- [60] Orlando A, Leandro G, Olivo M, Andriulli A, Cottone M. Radiofrequency thermal ablation vs. percutaneous ethanol injection for small hepatocellular carcinoma in cirrhosis: Metaanalysis of randomized controlled trials. *Am J Gastroenterol* 2009; 104 (2): 514-524.
- [61] Cho YK, Kim JK, Kim MY, Rhim H, Han JK. Systematic review of randomized trials for hepatocellular carcinoma treated with percutaneous ablation therapies. *Hepatology* 2009; 49 (2): 453-459.
- [62] Bouza C, Cuadrado TL, Alcàzar R, Parkinson ZS, Amate JM. Meta-analysis of percutaneous radiofrequency ablation versus ethanol injection in hepatocellular carcinoma. *BMC Gastroenterol* 2009; 9: 31-39.
- [63] Bruix J, Sherman M. Management of hepatocellular carcinoma. *Hepatology* 2005; 42:1208-1236.
- [64] Abdel-Wahab M, El-Ghawalby N, Mostafa M, *et al.* Epidemiology of hepatocellular carcinoma in lower Egypt, Mansoura Gastroenterology Center. *Hepatogastroenterology* 2007; 54 (73): 157-162.
- [65] Elefsiniotos IS, Diamantis ID, Dourakis SP, *et al.* Anticardiolipin antibodies in chronic hepatitis B and chronic hepatitis D infection, and hepatitis B-related hepatocellular carcinoma. Relationship with portal vein thrombosis. *Eur Gastroenterol Hepatol* 2003; 15 (7): 721-726.
- [66] Fujii T, Takayasu K, Muramatsu Y, *et al.* Hepatocellular carcinoma with portal tumor thrombus: Analysis of factors determining prognosis. *Jpn J Clin Oncol* 1993; 23 (2): 105-109.
- [67] Rabe C, Pilz T, Klostermann C, *et al.* Clinical characteristics and outcome of a cohort of 101 patients with hepatocellular carcinoma. *World J Gastroenterol* 2001; 7 (2): 208-215.
- [68] Llovet JM, Bustamante J, Castells A, *et al.* Natural history of untreated non surgical hepatocellular carcinoma: Rationale for the design and evaluation of therapeutic trials. *Hepatology* 1999; 29: 62-67.
- [69] Villa E, Moles A, Ferretti I, *et al.* Natural history of inoperable hepatocellular carcinoma: Estrogen receptors' status in the tumor is the strongest prognostic factor for survival. *Hepatology* 2000; 32: 535-539.
- [70] Giorgio A, Tarantino L, de Stefano G, *et al.* Ultrasound-guided percutaneous ethanol injection under general anaesthesia for the treatment of hepatocellular carcinoma on cirrhosis: Long-term results in 268 patients. *Eur J Ultrasound* 2000; 12 (2): 145-54.
- [71] Giorgio A, de Stefano G, Di Sarno A, *et al.* Radiofrequency ablation of hepatocellular carcinoma extended into the portal vein: Preliminary results. *J Ultrasound* 2009; 12: 32-37.
- [72] Giorgio A, de Stefano G, Di Sarno A, *et al.* Radiofrequency ablation of both medium size hepatocellular carcinoma (HCC) and accompanied with main portal venous (MPV) tumor thrombus in cirrhotic patients: A case control study. *Dig Liver Dis* 2009; 41: A7.
- [73] Giorgio A, Di Sarno A, de Stefano G, *et al.* Hepatocellular carcinoma with cirrhosis: Are patients with neoplastic main portal vein invasion eligible for percutaneous radiofrequency ablation of both the nodule and the portal venous tumor thrombus? *Am J Roentgenol* 2009; 193: (in press).